Breast Imaging | GP Guide

A practical guide for GPs following screening, breast density notification or clinical concern

Clinically reviewed by:

I-MED Radiologist
Dr David Hiller
MD, MSc, FRANZCR

I-MED Chief Medical Officer
Dr Luke Danaher
BAppSci (MRT), MBBS, FRANZCR

Examples of BI-RADS breast density categories:

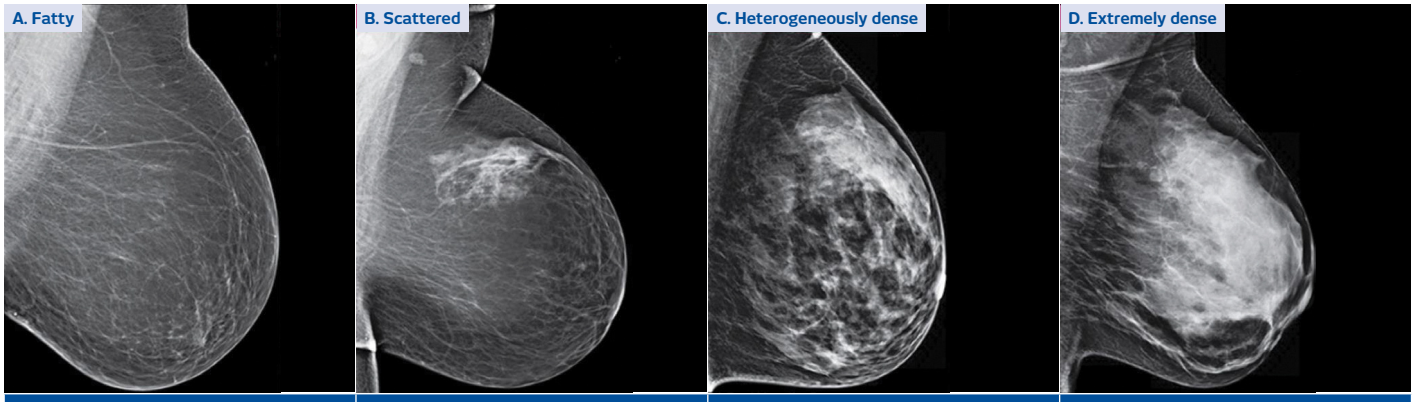

A - Almost entirely fatty	B - Scattered fibroglandular	C - Heterogeneously dense	D - Extremely dense
2D sensitivity ~90% Relative risk ~0.5^{X}	2D sensitivity ~90% Relative risk ~1.0^{X} (baseline)	2D sensitivity 84% Relative risk ~1.6^{X}	2D sensitivity 64% Relative risk ~2.6^{X}

Image credit: Covington M. Mammographic examples of breast density categories. Images courtesy of Matt Covington, MD, FSBI; reproduced/adapted with permission.

Original schematic of BI-RADS 5th Edition (ACR) density categories - not a clinical mammogram. Density is the ratio of fibroglandular to fatty tissue and cannot be determined by clinical breast examination. BreastScreen NSW. (n.d.). Mammographic density. NSW Government adapted from (Carney PA, Miglioretti DL, Yankaskas BC, et al. Individual and Combined Effects of Age, Breast Density, and Hormone Replacement Therapy Use on the Accuracy of Screening Mammography. Annals of Internal Medicine. 2003;138(3):168–175.)

McCormack VA, dos Santos Silva I. Breast density and parenchymal patterns as markers of breast cancer risk: a meta-analysis. Cancer Epidemiol Biomarkers Prev. 2006;15(6):1159–1169. - Bodewes F, van Asselt A, Greuter M and de Bock G (2022) 'Mammographic breast density and the risk of breast cancer: A systematic review and meta-analysis', The Breast, 66:62–68, doi:10.1016/j.breast.2022.09.007.

What changed - November 2025

National guidance for GPs changed in November 2025, with breast density now incorporated into guidance on screening discussions and next-step management.

The guidance was developed through multidisciplinary expert consensus, in collaboration with the University of Melbourne and in consultation with the Royal Australian College of General Practitioners, and was endorsed by the BreastScreen Australia Clinical Advisory Group[1]. It is intended to support GPs caring for patients who have been informed that they have dense breasts.

The guidance recommends that screening options be considered using **two factors together**: the patient's reported BI-RADS breast density category and their RACGP family-history risk category. This provides a more structured, risk-informed approach to discussing ongoing screening and, where appropriate, supplemental imaging.[1]

Move Beyond Density Alone: iPrevent and Tyrer-Cuzick

Based on the Australian Government guidance, GPs should use the iPrevent[2] or Tyrer-Cuzick / IBIS v8[3] as validated breast cancer risk-assessment tools to put breast density into the context of the woman's overall breast cancer risk. The guide recommends using these tools when a women has high breast density to calculate a woman's individual breast cancer risk.

The iPrevent tool has been validated in Australia, is patient-friendly and jargon-free, and typically takes 20–30 minutes to complete. It provides RACGP-aligned risk categories; average, moderate or high, along with a printable patient summary.

Tyrer-Cuzick / IBIS v8 Integrates the BI-RADS category or an exact Volpara density percentage (now part of Lunit). It takes around 3 minutes to complete and provides precise 10-year and remaining lifetime risk percentages.

[1] Australian Government Department of Health, Disability and Ageing. (2025, November). *Breast density GP guidance*. https://www.health.gov.au/sites/default/files/2025-11/breast-density-gp-guidance.pdf
[2] Peter MacCallum Cancer Centre. (n.d.). *iPrevent™*. https://iprevent.net.au/
[3] Ikonopedia. (n.d.). *IBIS risk assessment tool v8.0b: Online Tyrer-Cuzick model breast cancer risk evaluation tool*. https://ibis.ikonopedia.com/

IMEDACT473_0926

Referral Pathway for Above-average-risk Women[4]

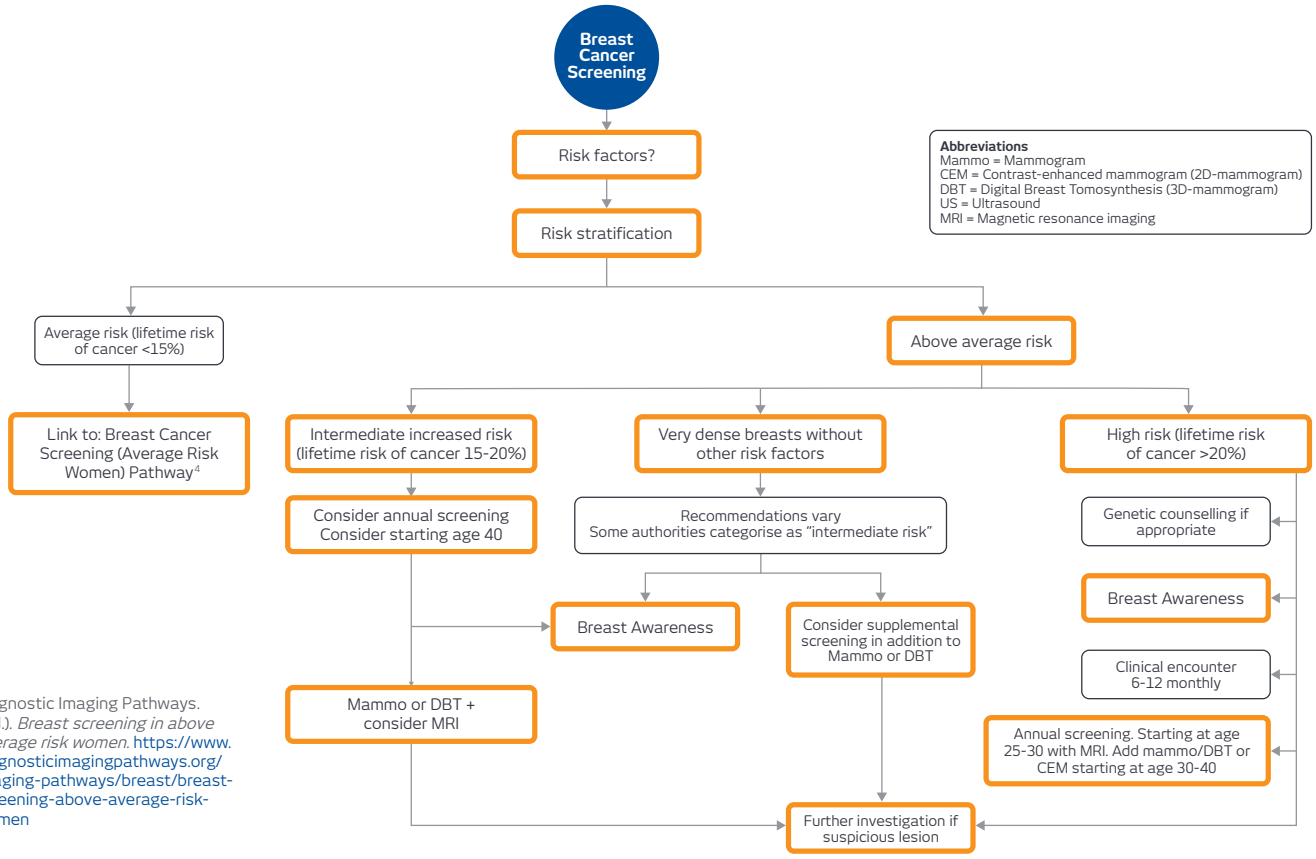

[4] Diagnostic Imaging Pathways. (n.d.). *Breast screening in above average risk women.* https://www.diagnosticimagingpathways.org/imaging-pathways/breast/breast-screening-above-average-risk-women

Breast Density and Screening: National Guidance for GPs

Breast density should be considered in the context of a woman's overall breast cancer risk. The table below outlines screening and supplemental imaging options for discussion based on breast density and RACGP family history risk based on the latest national GP guidance[1].

Breast density category	RACGP family history risk	Screening options for discussion
BI-RADS a or b	Average risk	Recommend mammography screening every 2 years
BI-RADS a or b	Moderate risk	Recommend mammography screening yearly or every 2 years
BI-RADS a or b	High risk	Refer to familial cancer services ***
BI-RADS c	Average risk	Recommend mammography screening every 2 years
BI-RADS c	Moderate risk	Recommend mammography screening yearly or every 2 years (following risk-informed discussion) at the interval recommended in your jurisdiction Review additional risk factors and consider using a risk assessment tool (e.g. iPrevent or Tyrer-Cuzick) to determine eligibility for MBS-funded MRI (Item 63464)** Consider supplemental imaging* with CEM or MRI where available (consider DBT or US if MRI and CEM are contraindicated or unavailable)
BI-RADS c	High risk	Refer to familial cancer services ***
BI-RADS d	Average risk	Recommend mammography screening every 2 years (following risk-informed discussion) Consider alternative/additional imaging* with CEM or MRI where available (DBT or US if MRI and CEM are contraindicated or unavailable)
BI-RADS d	Moderate risk	Recommend mammography screening yearly or every 2 years (following risk-informed discussion) at the interval recommended in your jurisdiction Calculate breast cancer risk using a risk assessment tool (e.g. iPrevent or Tyrer-Cuzick). • If lifetime risk estimation >30% (or a 10-year absolute risk estimation >5%), offer additional MBS-funded MRI** • If lifetime risk estimation <30% (or a 10-year absolute risk estimation <5%), offer additional imaging* with CEM or MRI where available (DBT or US if MRI/CEM are contraindicated or unavailable)
BI-RADS d	High risk	Refer to familial cancer services ***

P. J., Mali, W. P. T. M., & van den Bosch, M. A. A. J. (2019). Supplemental MRI screening for women with extremely dense breast tissue. The New England Journal of Medicine, 381(22), 2091–2102. https://doi.org/10.1056/NEJMoa1903986

* Additional imaging screening tests are associated with an increase in false positive results and may incur out of pocket costs.

** Patient may be eligible for a Medicare rebate (Item 63464) if <60 years old, but this requires referral from a specialist, which may incur additional out of pocket costs.

*** Refer to eviQ[5] General Practitioner Referral Guidelines for cancer genetics assessment, which includes a list of Genetic Services by state and type of service.

[5] eviQ. (2025). General practitioner referral guidelines for cancer genetics assessment (ID 1147, Version 9). Cancer Institute NSW.

Breast Imaging Options

Detection yield is additional cancers found per 1,000 women screened, over and above standard mammography.

Procedure	Role	Detection yield	Access & referral	MBS considerations
3D mammography (breast tomosynthesis, DBT)	Thin-section images reduce the tissue overlap that limits 2D mammography. In the November 2025 pathway DBT is a **fallback** supplemental option in dense breasts - considered where MRI and CEM are contraindicated or unavailable.	1.7 additional cancers per 1,000[6]	Widely available; GP referral. Sites listed on page 4. Additional radiation versus 2D.	Item 59302 (3D diagnostic mammogram) where malignancy is suspected because of past breast malignancy, significant family history of breast or ovarian malignancy, or symptoms/signs found on examination. **Not** MBS-funded as a screening test on the basis of density alone; potential out-of-pocket cost.
Breast ultrasound	First-line alongside mammography for a focal symptom, and in women under 35. **Not** recommended as a non-targeted screening test in asymptomatic women - false positives drive a benign biopsy cascade. Operator dependent.	4 additional cancers per 1,000[6]	Widely available across the network; GP referral. Lower out-of-pocket cost than the contrast modalities.	**Item 55076** - where malignancy is suspected, in association with mammography, or in young women under 35.
Contrast-enhanced mammography (CEM)	Iodinated contrast highlights leaky tumour neovascularisation against background glandular tissue - the same basis as MRI. The pragmatic problem-solver for dense breasts.	~16 additional cancers per 1,000[6]	**Direct GP referral** - Selected I-MED sites only (page 4). Suits patients who are claustrophobic (10–15% do not tolerate MRI) or cannot manage 20–30 min prone. Not suitable with iodine allergy or renal contraindication.	**No MBS item number** for supplemental imaging following screening, self-funded. Indicative out-of-pocket $150-$250.
Breast MRI	The highest-sensitivity supplemental test, and the required modality for high-risk women under 40 (avoiding cumulative ionising radiation) and where iodinated contrast is contraindicated. May be preferred where the patient cannot tolerate compression.	~16 additional cancers per 1,000[6]	**Specialist referral required** for the screening item - GPs cannot order Item 63464 directly. Dedicated breast coil, gadolinium contrast, ~20–30 min prone; 10–15% intolerance.	**Item 63464** - asymptomatic, under 60, high risk on one or more listed criteria including lifetime risk >30% or 10-year absolute risk >5% on a clinically relevant algorithm; once in any 12 months; not with 55076 or 55079. Items **63467, 63487, 63489, 63531, 63533, 63547** cover defined diagnostic scenarios. Indicative total out-of-pocket $350-$700+.
Breast PET	**No role in density assessment or supplemental screening.** Used for staging and suspected recurrence in diagnosed disease. Included so the boundary is explicit.	Not applicable.	Specialist referral; PET-capable sites only.	**Item 61524** - staging of locally advanced (Stage III) breast Cancer in a patient considered potentially suitable for active therapy. **Item 61525** - evaluation of suspected metastatic, or suspected locally or regionally recurrent, breast carcinoma in a patient considered suitable for active therapy.

I-MED Radiology Network - Answers, access and appropriate imaging

Comprehensive breast imaging. Expert support when the next step isn't clear.

For many women, a breast density notification raises questions they were not expecting - and their GP is often the first person they turn to. I-MED can support you in considering the appropriate next step, with access to a comprehensive range of breast imaging services and subspecialised radiologist expertise.

- **Comprehensive breast imaging in one network**
  Access a range of breast imaging options across available across the network.
- **Radiologist advice when you need it**
  Our subspecialised breast radiologists can help where the appropriate imaging pathway is less clear, including questions around MRI eligibility, contrast contraindications or patient tolerance.
- **Straightforward referral and access**
  Use our online clinic finder to identify clinics offering breast imaging, and e-referral to support faster booking and appropriate protocoling before the patient attends.

Scan for the complete Breast Imaging Medicare Rebate Guide, with full item descriptors and frequency limits.

[6] BreastScreen NSW

IMEDACT473_0926

Where to refer – ACT

For more information on our clinics and services visit **i-med.com.au**

ACT Location	Address	Phone	Fax	3D Mammography (Tomosynthesis)	Breast Ultrasound	Contrast Enhanced Mammography	Breast MRI	Breast PET
Belconnen	40 Cameron Avenue, Belconnen 2617	02 6109 6900	02 6109 6949	✔	✔		✔	
Deakin	Canberra Specialist Centre, Suites A2 & B2, 161 Strickland Crescent, Deakin 2600	02 6124 1900	02 6124 1950		✔			
Tuggeranong	167 Soward Way, Greenway ACT 2900	02 6293 2922	02 6293 1212		✔			
Woden	Woden Specialist Medical Centre, Ground Floor, 90 Corinna Street, Phillip 2606	02 6214 2222	02 6281 4261	✔	✔			

Referring to I-MED

Check the site first. Use the online clinic finder to confirm the location offers the modality you need before writing the referral -CEM in particular is available at selected sites only.

Use e-referral where possible. Patients book up to 4x faster, the risk of misinterpretation drops, and the patient can be protocolled before attending so the study is available and contraindications are checked.

Ask a radiologist. Where MRI eligibility, contrast contraindications or patient tolerance are in question, our subspecialised breast radiologists can advise on the appropriate test before referral.

IMEDACT473_0926